

Curodont™ Repair Application for dentists

Before the appointment for Curodont™ Repair application

- 1 Identification and diagnosis of early enamel non-cavitated carious lesions. (Table 1)
- 2 Demonstration and explanation of the findings to the patient.
- 3 Patient counselling and demonstration of possible caries progression (charts, brochures, videos).
- 4 Obtaining patient consent and managing expectations.
- 5 Instructing patients to perform routine oral hygiene measures before the appointment.

Table 1: Indications for use of Curodont™ Repair, according to popular caries classification systems

ADA Caries classification system ¹	SOUND	INITIAL			MODERATE		ADVANCED	
Clinical Presentation	No clinically detectable lesion. Dental hard tissue appears normal in color, translucency, and gloss, with no surface change.	Earliest clinically detectable lesion compatible with mild demineralization, the tooth is visually non-cavitated. The lesion is limited to enamel or to a shallow depth in dentin. Early, mild forms may only be visible after drying. When established, lesions may appear white or brown, with a loss of gloss of enamel.			Obvious and established shallow cavitation of enamel with evidence of moderate demineralization of dentin.		Enamel is fully cavitated with definite and established exposure of dentin, which is severely demineralized.	
International Caries Detection And Assessment System (ICDAS) II ²	Score 0	Score 1	Score 2	Score 3 ³	Score 4	Score 5	Score 6	
Appearance of Occlusal surfaces (Pit and fissure)								
Appearance of smooth surfaces, including cervical and root surface								
Radiographic appearance of proximal surfaces With ICCMS radiographic scoring ⁵	 0	 RA 1	 RA 2	 RA 3	 RB 4	 RC 5		
E0-E2, D1-D3 Notation System ⁶	E0	E1	E2	D1 ⁴	D2	D3		
Marthaler/WHO classification ⁷	D0	D1	D2	D3	D4	D4		

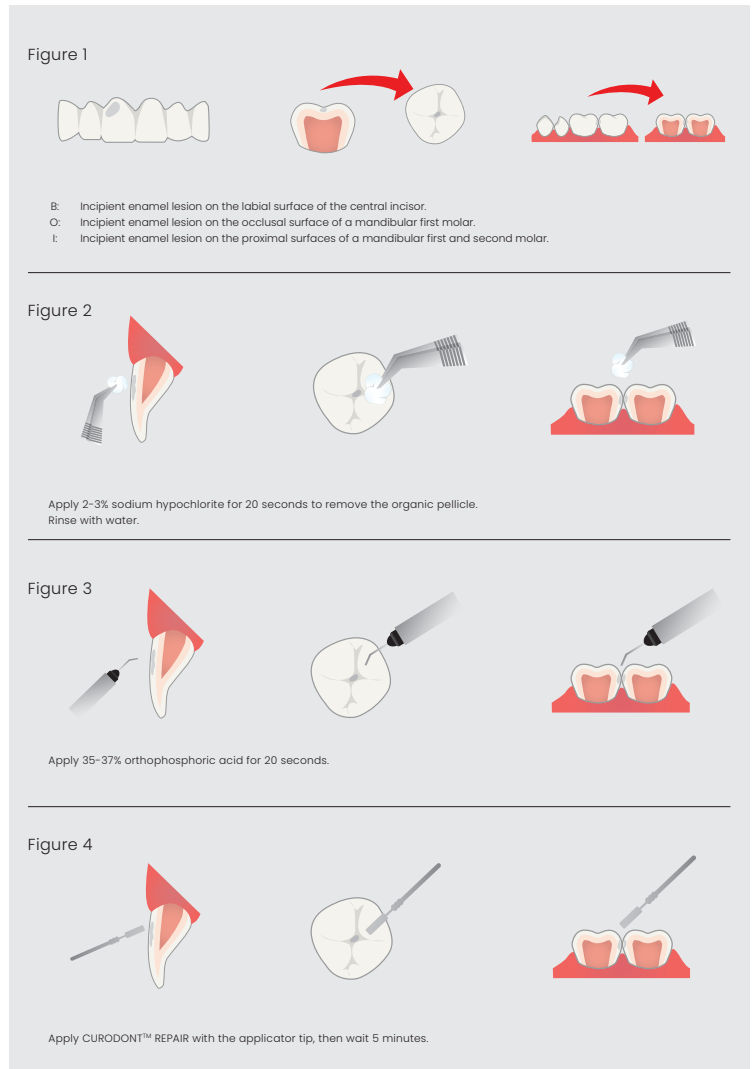
Scope of Curodont™ Repair

¹Young DA, Nový BB, Zeller GG, Hale R, Hart TC, Truelove EL; American Dental Association Council on Scientific Affairs; American Dental Association Council on Scientific Affairs. The American Dental Association Caries Classification System for clinical practice: a report of the American Dental Association Council on Scientific Affairs. J Am Dent Assoc. 2015 Feb;146(2):79-86.
²<https://iccms-web.com/uploads/asset/592848be55d87564970232.pdf>. Accessed 01/02/2022
³Occlusal and smooth surface microcavities (ICDAS score 3) may be treated to arrest caries progression, but 'filling' of the microcavity is not possible.
⁴D1 proximal lesions can be treated with Curodont Repair only if not cavitated.
⁵<https://www.iccms-web.com/uploads/asset/592845add7ac8756944059.pdf>. Accessed 01/02/2022
⁶Anusavice K. Present and future approaches for the control of caries. J Dent Educ. 2005;69(5):538-85
⁷Marthaler TM. A standardized system of recording dental conditions. Helv Odontol Acta 1966;10:1-18.

During the appointment for the application of Curodont™ Repair

- 6 Perform oral prophylaxis, especially in the area to be treated to eliminate any calculus/ plaque/materia alba.
- 7 Use cheek retractors and cotton rolls in the buccal and lingual vestibules adjacent to the area in question. Use of a rubber dam is optional.
- 8 Dip a small cotton pellet, held in tweezers, in 2-3% sodium hypochlorite.
- 9 Use the saturated cotton pellet for 20 seconds to clean the area in question and remove the organic pellicle. (Figure 2)
- 10 Rinse with water.
- 11 Apply 35-37% orthophosphoric acid to the area in question for 20 seconds and then, rinse. Unwaxed dental floss may be used to distribute it in the interdental space. (Figure 3)
- 12 Pat the tooth so that the area to be treated is semi-dry. Aggressive drying with a three-way is not recommended.
- 13 Take one CURODONT™ REPAIR applicator tip and press the sponge into the material. Withdraw the sponge and press it onto the lesion. For occlusal lesions, pressing the sponge is enough to distribute the material into the lesion; spreading it over the tooth is unnecessary. Use one applicator per lesion.
*If interproximal, lesions may be present on the distal surface of the mesial tooth and mesial surface of the distal tooth. In such case, one applicator may be used for two lesions. (Figure 4)
- 14 Wait 5 min. Do not rinse or ask the patient to spit.
- 15 Discharge the patient with routine instruction and emphasize the need to maintain good oral hygiene.

Buccal/Lingual Caries Occlusal Caries Interproximal Caries



After the appointment

- 16 Reinforce with the patient the importance of:
 - Keeping treated area clean
 - Performing a daily thorough oral hygiene
 - Ensuring a healthy, balanced diet



60.0560.02

**For More Inquiries, Do Not Hesitate to Contact
the Authoritative Agent in Bahrain**